

IMMEDIATE LOADING OF DENTAL IMPLANTS USING INTRAORAL WELDING TECHNIQUE

CASE REPORT



Dr Kristian Gerga
Center of cosmetic dentistry Dr Gerga
Banatsko Novo Selo

INTRODUCTION

Patients demands on immediate functional and esthetical dental rehabilitation has resulted in development of immediate implant placement and immediate loading.

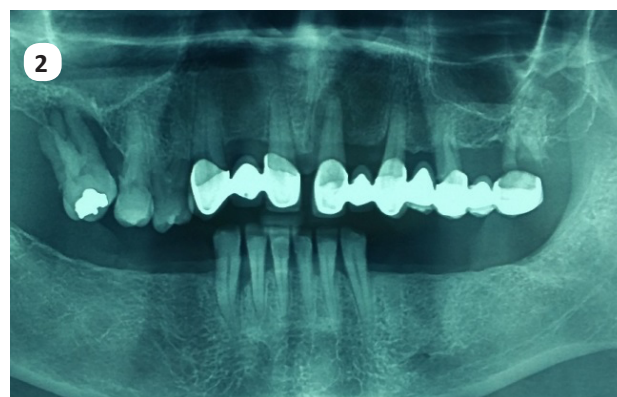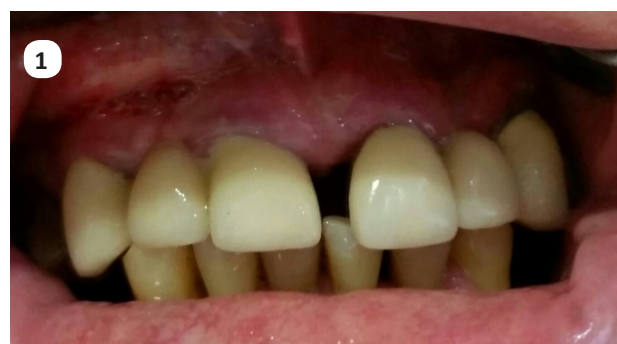Immediate implant loading is loading with temporary or permanent dental restorations which generate mild occlusal contacts with the antagonist, and are set on the implants immediately or up to 48 hours after the surgical procedure (Oral Implantology, School of Dental Medicine, University of Belgrade, Milan Jurisic editor).

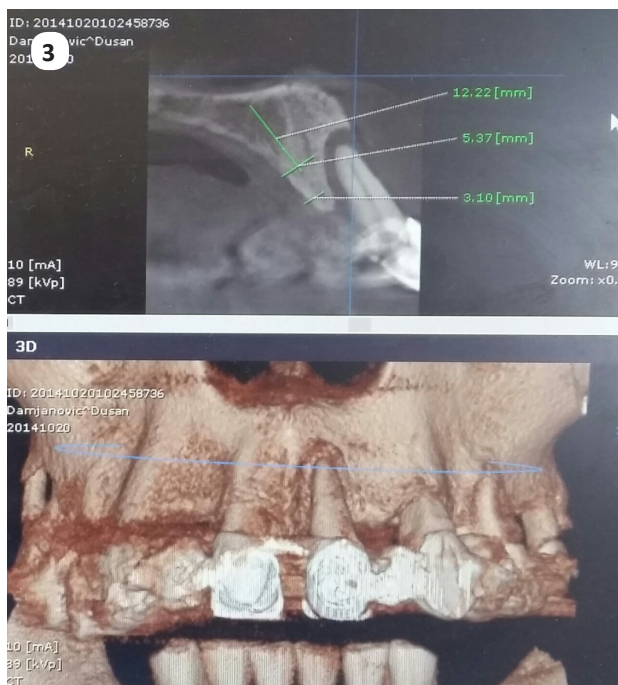
Protocol of immediate implant loading is affected by many factors: bone type, surgical procedure, implant design, primary stability of over 35 Ncm, the length of the implant-not less than 10 mm, the type of temporary prosthetics, etc. The aim of this article is to present a clinical case of immediate implants loading using the technique of intraoral welding.

Intraoral welding is a technique that stabilizes implants with rigid splint in the early stage of osseointegration, thus enabling their immediate load. The technique was first developed by Pierluigi Mondani in 1970. Intraoral welding is based on a physical process of syncrystallization in the presence of argon gas.

CASE REPORT

The patient age 63 came to our clinic with pain and swelling in his upper jaw. Clinical examination shows the presence of old metal ceramic crowns with improper marginal sealing, root caries lesions, chronically inflamed gingiva, periodontal pockets, all teeth loose (figure 1). Performed analysis of 3D and OPT (Figure 2, 3) indicated extraction of remaining teeth. Patient wanted fixed prosthetic restoration. Treatment plan was: 6 implants in upper and 6 in lower jaw, intraoral welding and immediate loading.





The main condition for the implementation of this plan was achieving primary stability of the each implant greater than 35 Ncm. In case of inability to achieve an adequate primary stability backup plan were implants loading after a period of 3 to 6 months of their surgical insertion. Temporary prosthetic solution in this case is two total dentures lined with soft resin.

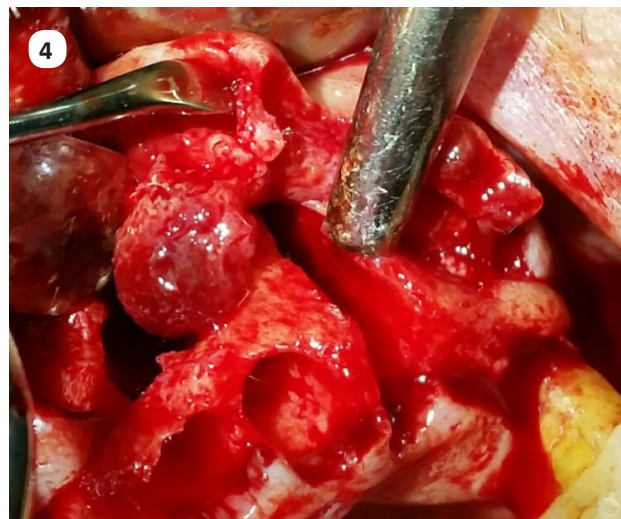The written consent of the patient was obtained and we started with treatment.

A day before surgical procedure we administered antibiotic therapy (Amoksiklav Lek 625 mg and Orvagil 400 mg) and mouth rinse with 0,20 % CHX (Curasept ADS).

Before surgery blood sample was taken to obtain PRF.

The surgical field is anesthetized using 4% Articaine hydrochloride (Ubistesin Forte 1: 100 000, 3M ESPE) and 2ml dexamethasone sodium phosphate (Dexason, 4 mg) was administered to minimize postoperative edema.

Gingival incision is made in the usual manner, full thickness (mucoperiosteal) flap was created, the teeth were extracted and great attention is paid to wound debridement (Figure 4).



After removal of inflamed granulation tissue little autologous bone was collected, grounded in a hand mill and preserved for the purposes of grafting.

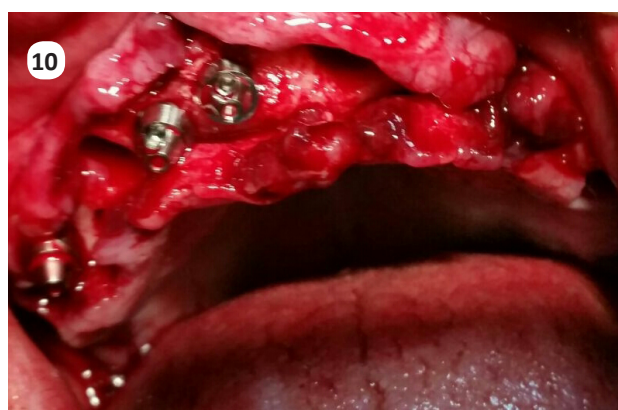
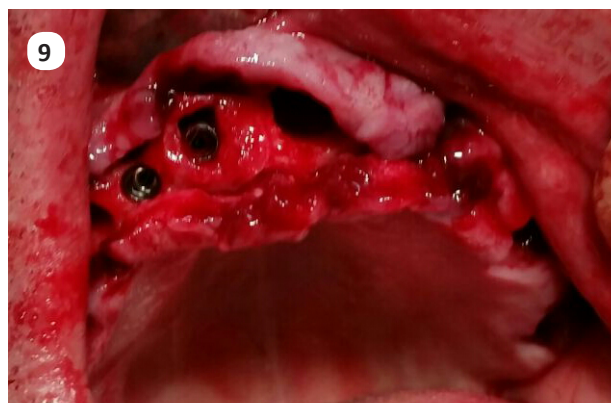
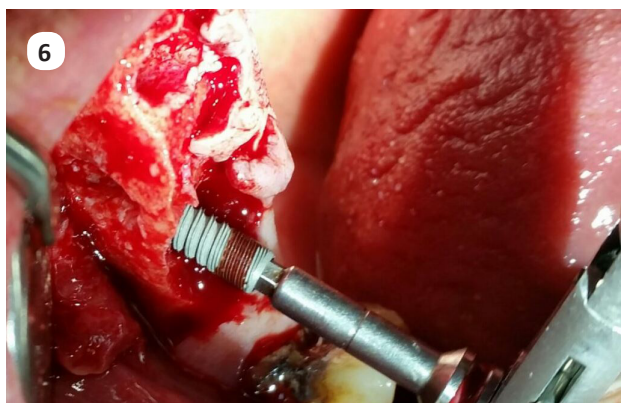
Implant (Esthetic Line, C-Tech, Italia) site preparation was performed in standard way according manufacturer protocol (Fig 5).



Large alveolar defects and the need for obtaining primary stability greater than 35 Ncm have caused implant angle in certain positions greater than 25 ° (Fig. 6).

Using Multi Unit Abutment (MUA, C-Tech, Italy) and their ability to correct angulation of up to 35°, we managed, without much difficulty, to overcome certain obstacles.

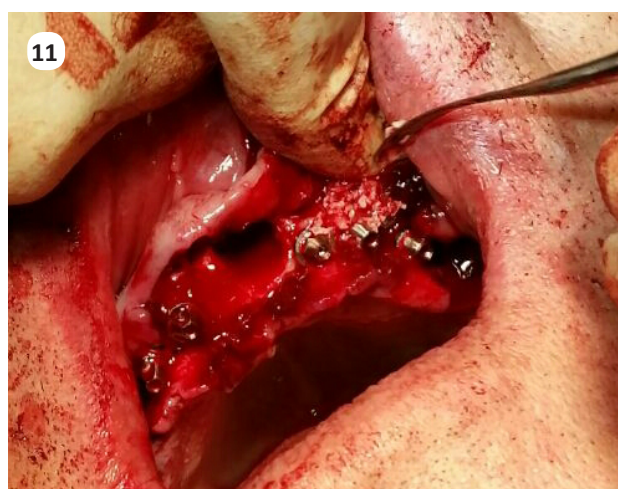
Manufacturer C-Tech offers MUA of 17o and 30o (Fig.7).

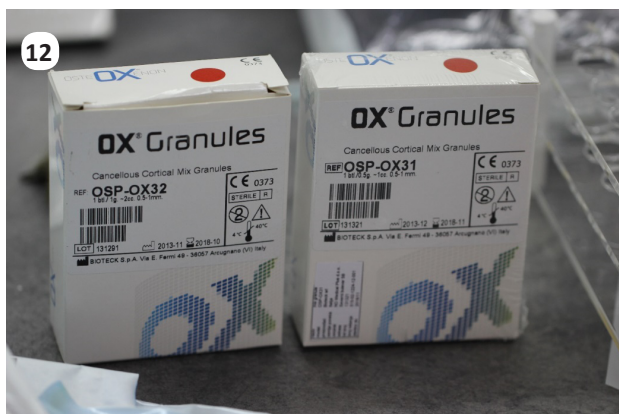

During the operation we used a set of abutment for a prosthetic planning (Technical Planning Abutments, C-Tech, Italy) (Fig. 8), which significantly facilitates the choice of MUA, which are placed on the implants and tighten to 25 Ncm (Figures 9, 10).

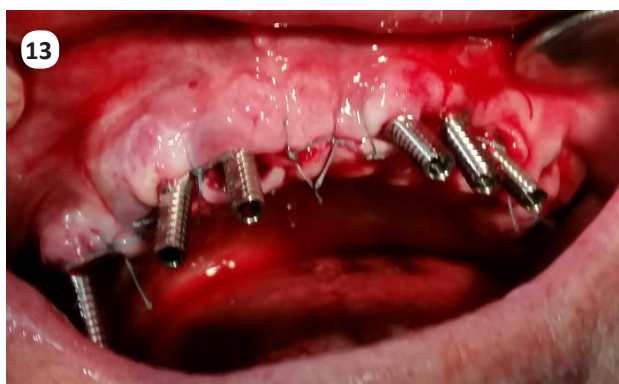
Immediately after placing the MUA bone defects grafting is done (Figure 11).

For this purpose, the mixture of xenograft (OSP OX-31, OSP-OX32, Bioteck, Italy) (Fig.12), autograft and PRF are used. Grafted regions are covered with a collagen membrane (BCG XC30, Bioteck, Italy) and PRF membrane.





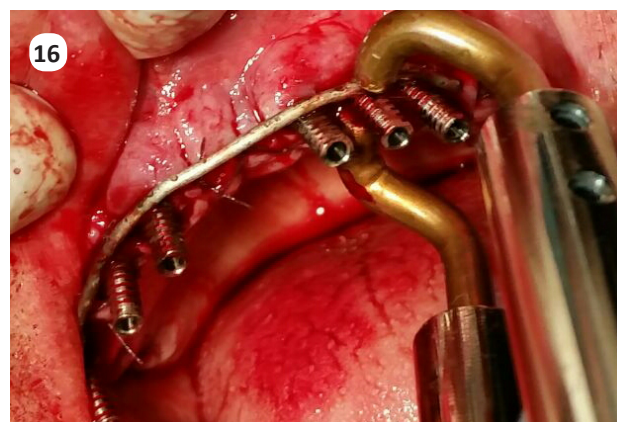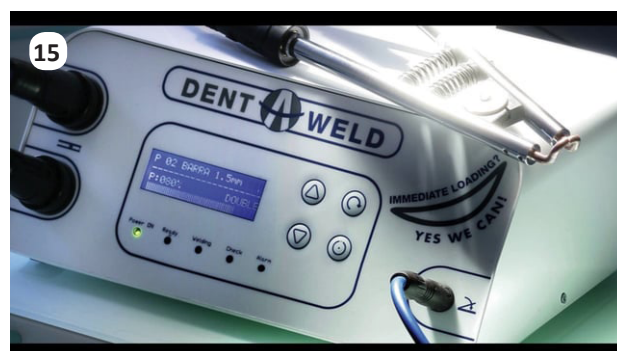Before the suture temporary titanium abutment (Temporary Titanium Abutment, C-Tech, Italy) have been placed on MUA (Figures 13, 14).



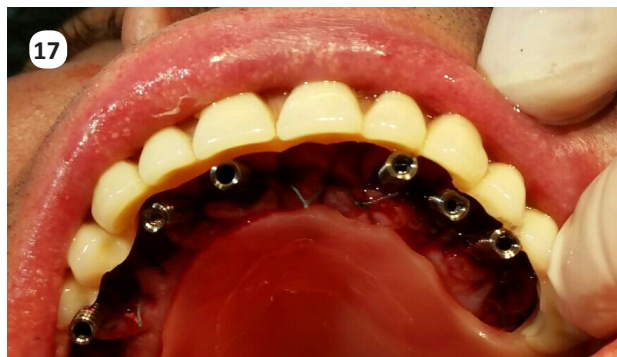Their function was to provide a base for intra-oral welding and provide fixing of the temporary tooth restoration.

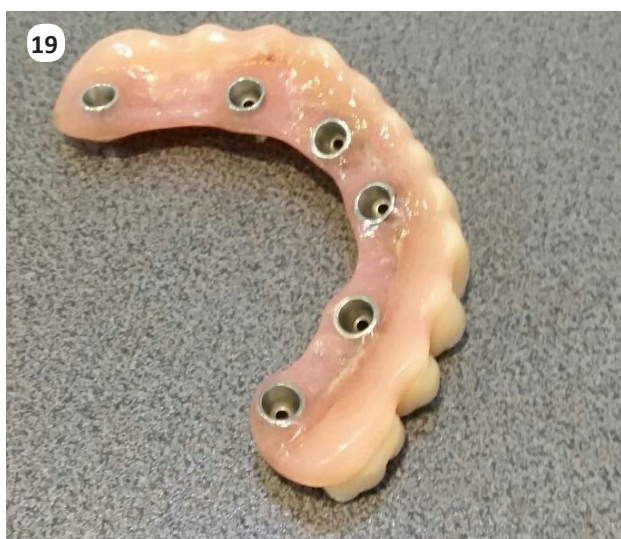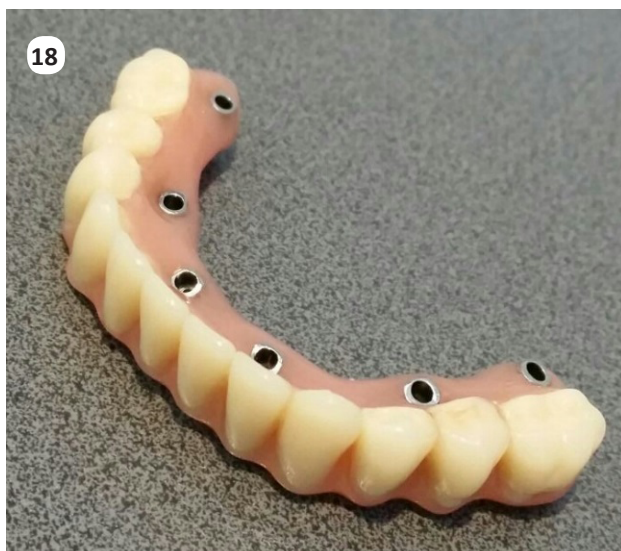After deperiosting appropriate mobility of mucoperiosteal flap is obtained and conditions for

suturing without tension at the edges of flap. Suturing is done in two layers setting horizontal mattress sutures in combination with a single suture. Intraoral welding is performed by Dent Weld device (Sweden Martina, Italy) and 1.4 mm titanium profile (Fig. 15, 16). Titanium profile is positioned on temporary abutments passively without tension.



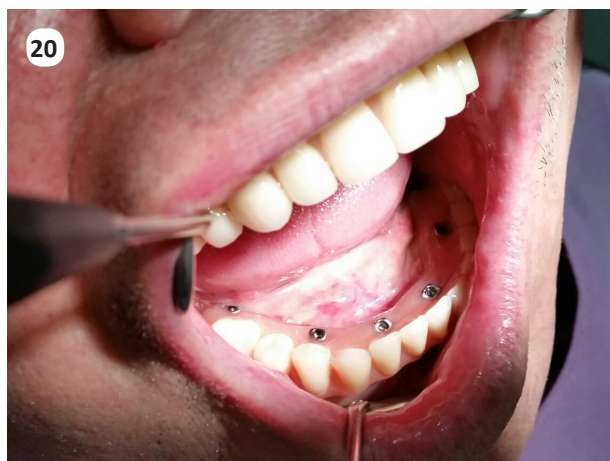
We made a hole on previously prepared total prosthesis so the whole welded construction goes through it (Fig. 17).



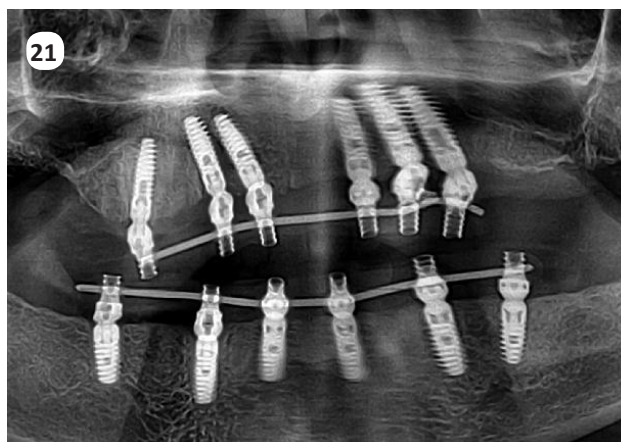


Self-adhesive resin was applied between the prosthesis and the abutments. Construction was unscrewed and transformed in bridge (Fig. 18, 19). Temporary acrylic bridge is placed on MUA and tightened by force of 15 Ncm (Fig. 20).

Special attention was given to the occlusion and articulation in order to minimize the detrimental effect of the horizontal forces. The patient was instructed about the consumption of soft foods in the coming months and the way to maintain oral hygiene.



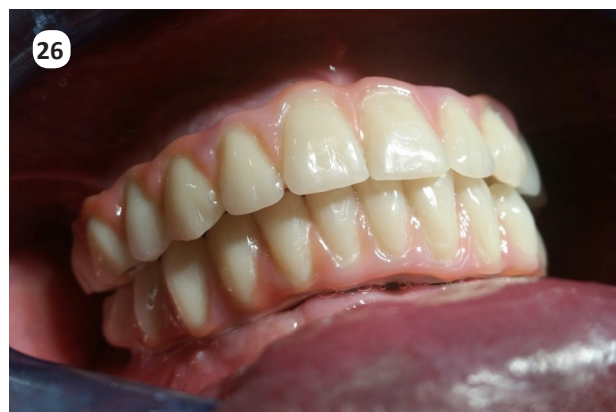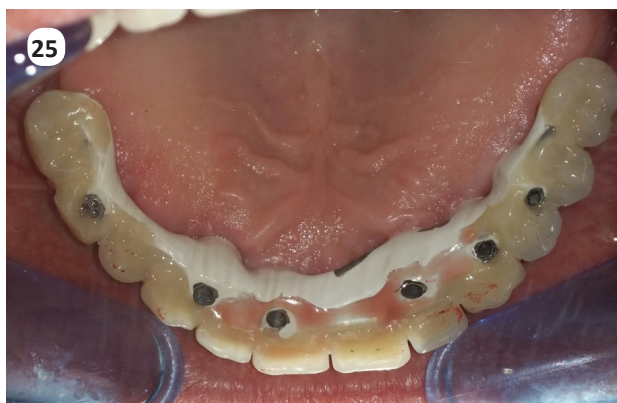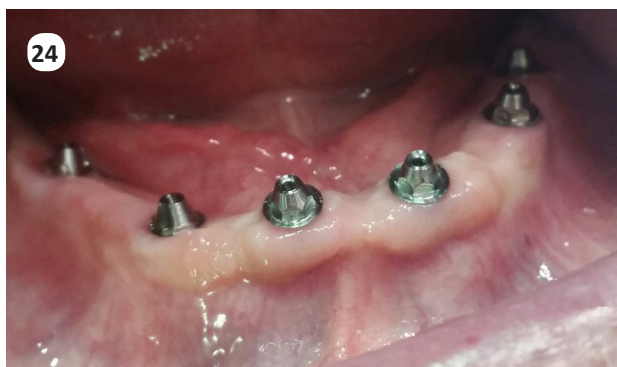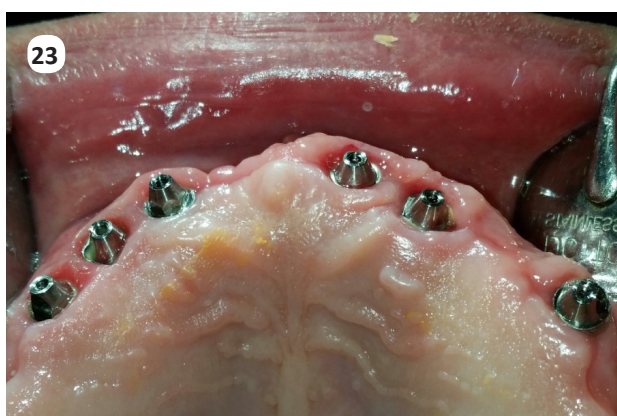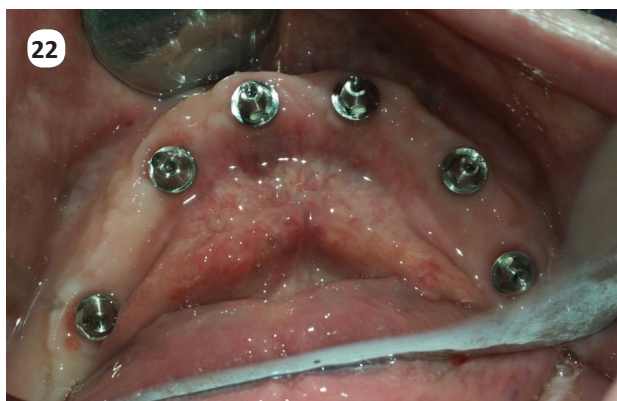Six months later control OPT was made and we noticed complete implants osseointegration. The level of cortical bone around the implant was completely preserved (Figure 21).



After removal of the temporary teeth we found nicely formed gingival sulcuses without any signs of peri-implantitis. (Figures 22, 23, 24).

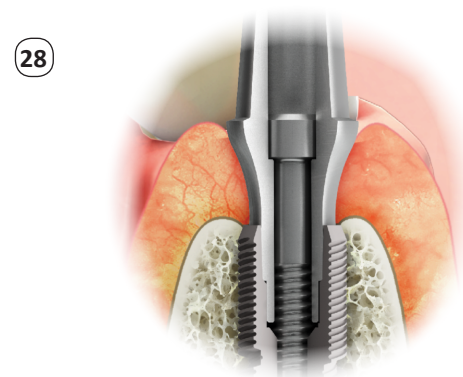

Open tray impression was taken at the abutment level thus we avoid several times abutments removing and installing which significantly contributes to maintain the level of cortical bone around the implant.

For the definitive work has been chosen screw retained restoration from BioHPP (Bredent, Germany) (Figure 25, 26) with the special thanks to Dental Lab "Čakan Dental".



CONCLUSION

The global market offers a large number of dental implants from different manufacturers -at the moment around 4000th of them. Each implant system has its advantages and disadvantages. EL implant system (C-Tech, Italy) we used in this case was able to meet most of our demands thanks to its design and prosthetic solutions (Figure 27, 28).



The advantages of intraoral welding are:

- fixation of the great number of implants at early stage of osseointegration,
- creation of a fixed block structure without tension,
- redistribution of occlusal and horizontal forces on all implants,
- reducing fracture risk of temporary structures

Immediate loading with the use of intraoral welding is functionally and aesthetically successful treatment.

Intra-oral welding can meet the needs of business and socially active people. The surgical and prosthetic procedures are performed on the same day. The patient will leave dental office functionally and aesthetically prepared for everyday work and communication.

